

Histological Study on the Sensory Receptors of the Teat Skin in Sarabi Cattle

Hamidreza Ferdowsi ^{1*}, Masoud Adib Moradi ², Mohammadreza Asadi ¹

¹ Institute of Scientific-Applied Higher Education of Jihad-e-Agriculture, Agricultural Research, Education and Extension Organization, Tehran, Iran

² Department of Basic Sciences, Faculty of Veterinary Medicine, University of Tehran, Iran

Received: 25 September 2017

Accepted: 24 October 2017

Published: 01 December 2017

Abstract

Sarabi cattle are found in Iran and Azerbaijan. They are used for both dairy and meat production. A histological study was carried out on the teat of Sarabi cattle for the first time in Iran. A total number of five adult and healthy cows were selected and after slaughtering, tissue samples were taken from different parts of the teat skin. After fixation in 10% formalin, they were transferred into the tissue processor. Paraffin blocks were made and thin sections of 6 μ , were cut. The sections were subjected to stain by Hematoxylin and Eosin. They were studied under the light microscope and photo micrographs were taken. The results show that the teat consists of teat sinus, teat wall, teat canal and teat orifice. Teat wall includes three separable strata: skin, middle layer and mucosal layer. Teat skin contains an epidermis and dermis, but there is no evidence of hypodermis existence in contrast with the other parts of the body. Dermis is formed from networks of collagen fibers, blood vessels, circular smooth muscle and nerve fibers. Meissner's corpuscles are found in the dermal papillae particularly in the connective tissue of teat canal. Myelinated nerve fibers are also seen in this region.

Keywords: Histology; Sarabi Cattle; Sensory Receptors; Skin; Teat

How to cite the article:

H. Ferdowsi 1, M. Adib Moradi 2, M. R. Asadi 1, , *Histological Study on the Sensory Receptors of the Teat Skin in Sarabi Cattle*, *Medbiotech J.* 2017; 1(4): 172-174, DOI: 10.22034/mbt.2017.87070

©2017 The Authors. This is an open access article under the CC BY license

1. Introduction

The Sarabi indigenous cow is one of the major regional dual purpose cows in Iran, which has a strong adaption to cold weather, diseases and parasites. The breed was imported from Gharabagh and breeds in Sarab, Mianeh and Ardebil regions of Iran (Khansefid, 2009). Individuals of this breed are typically red (Mason, 1996). Although Sarabi is a dual purpose cow, the milk production of this breed is noticeably higher than other Iranian vernacular cow breeds [1]. The average milk yield in this breed is 10 kilograms daily with an approximately 4.5% fat. Also production up to 20 kilograms daily can be seen individually [2].

Milk let-down is the natural process used by the cow to help remove milk from the udder. This process is brought about by the release of the oxytocin hormone from posterior pituitary gland under control of hypothalamus, following a suitable stimulus being received by the cow. The stimulus may be visual, heard or felt and should be predictable and consistent at every milking. Most importantly it should not induce fear in cows. It is commonly thought that genetic selection has ensured that most commercial cows will let-down freely without physical contact with the teats. Handling of the teats however, is a strong stimulus for let-down with research showing that at least 15 seconds of massage per cow is required to effect an

* Corresponding Author's Email: ferdowsi_hr@yahoo.com

appreciable change in milking characteristics. After release, oxytocin travels through the blood stream and has a direct effect on small muscle cells that surround the milk-producing cells in the udder. Oxytocin causes these myoepithelial cells to contract and squeeze the milk into the milk ducts and so towards the teats. The pressure of the milk being forced into the ducts and down towards the teat causes the teat to swell with milk and become “plump” with milk. It takes between 60 and 90 seconds for the teats to become plump with milk after let-down has been initiated [3]. A close study on the sensory receptors of teat skin would be very important to understand the physiology and pathology of milk let-down. Histological study of sensory receptors of the teat skin in Sarabi cattle was carried out for the first time in Iran.

2. Methodology

In order to histological study of the sensory receptors in areola and skin of the teat of Sarabi cattle, five adult and healthy cows were selected and after slaughtering, tissue samples were taken from different parts of the skin and areola of the teat. After fixation in 10% formalin, they were transferred into the tissue processor. Paraffin blocks were made and thin sections of 6 μ , were cut. The sections were subjected to stain by Hematoxylin and Eosin. They were studied under the light microscope and photo micrographs were taken.

3. Results

3.1 Macroscopic investigation

Each quarter has a separate teat with 7–8 cm length and 3 cm diameter. The teats vary in shape from cylindrical to conical. The results show that the teat consists of teat sinus, teat wall, teat canal and teat orifice. Each teat has a strong structure that protects it from excessive pressure due to the calf sucking, milking machine or hand milking. Despite the skin of the mammals, teat skin in Sarabi cattle is tightly attached to the underlied tissues and thus promotes teat resistance.

3.2 Microscopic investigation

Teat wall includes three separable strata: skin, middle layer and mucosal layer. Teat skin contains an epidermis and dermis, but there is no evidence of hypodermis existence in contrast with the other parts of the body. Epidermis consists of keratinized stratified squamous epithelium and the thickness increases towards the teat orifice. Dermis is formed from networks of collagen fibers, blood vessels, circular smooth muscle and nerve fibers. Dermal papillae projects into the epithelial undulations at the dermo-epidermal junction. Meissner's corpuscles are found in the dermal papillae particularly in the connective tissue of teat canal (Figure 1)

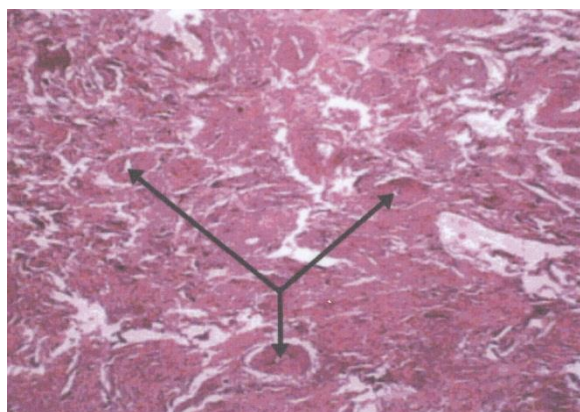


Figure 1. Teat dermis (H&E $\times 100$). Arrow: Blood vessels.

Myelinated nerve fibers are also seen in this region (Figure 2).

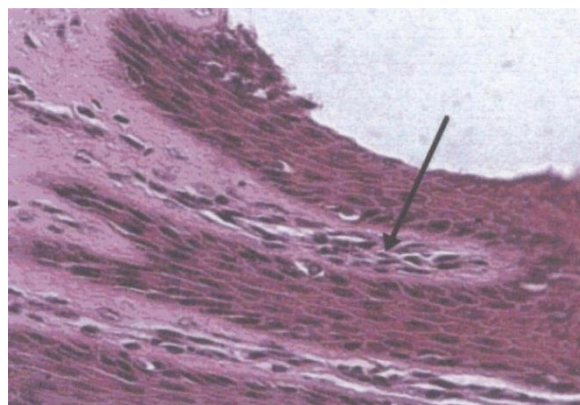


Figure 2. Dermal papillae (H&E $\times 400$). Arrow: Meissner's corpuscles.

Middle layer (Second layer) is the thickest layer of the teat wall that contains numerous smooth muscle bundles, developed vascular plexus and peripheral nerve fibers (Figure 3).

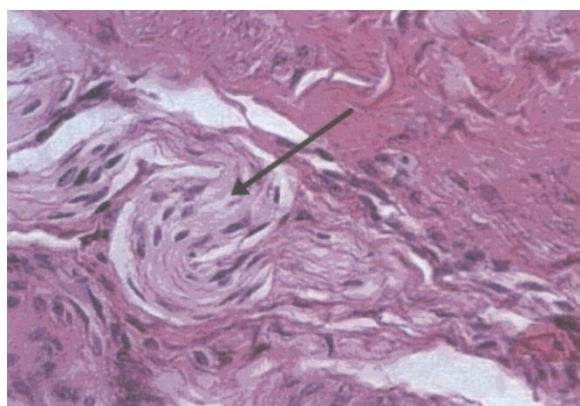


Figure 3. Middle layer (H&E $\times 400$). Arrow: Peripheral nerves. Mucosal layer is the innermost layer of the teat wall. Teat canal epithelium was thicker than teat skin epithelium (150 vs. 110 μ) with a remarkable increase in keratin and stratum granulosum.

4. Discussion and Conclusion

The bovine teat canal is highly specialized in its unique function of preventing both leakage of milk

and entry of bacteria and thereby plays a major role in the defence of the udder against mastitis [4]. The surface of the bovine and porcine teat is covered by glabrous, aglandular, stratified squamous epithelium [5]. In the mare, bitch and queen abundant sebaceous glands and fine hairs are present [6]. Nerve ends are located in the teat, in such a way that responds well to the hormonal neural stimuli. Characteristic of teat receptors in rabbit were studied by recording electrophysiologic wave techniques for afferent nerves and it was shown that teats are provided with mechanical receptors sensitive to suckling and pressure [7]. Hebb and Linzell (1970) reported a great number of nerve fibers in the arteries and arteriols that forms a plexus in the vessel wall [8]. Some of these fibers exist near the teat canal wall, but none of them ends to the alveolus and myoepithelial cells. In addition to the nerve fibers that end to the ducts, it was found many nerve fibers near the teat orifices. It was shown that goats can differentiate left and right udder stimulation. Numerous sensory nerve fibers in the middle layer conduct impulses to the CNS and oxytocin is released from neurohypophysis. It was indicated that there are mechanical receptors in the teat of rabbits [9,10] In the distal portion of the teat, there is a high density of circular smooth muscle surrounding the teat canal. It was indicated that the aggregation of muscular tissue in this area in heifers is less than the delivered cows [11,12].

References

1. Khansefid, S. M. 2009. An introduction to Sarabi cow breed – a vernacular cow breed of Iran. Nolan Special Magazine on Dairy cows. No 3/Jan-Mar.
2. Mason, I. L. 1996. *A World Dictionary of Livestock Breeds, Types and Varieties*. 4th edn. CAB International.
3. Klindworth, D., J. Campbell, R. Greenall. 2003. CowTime Guidelines for milk harvesting. Dairy Research and Development Corporation. Available on the Cow Time Website, www.cowtime.com.au.
4. Paulrud, C. O. 2005. Basic Concepts of the Bovine Teat Canal. *Vet Res Commun*. 29(3): 215-245.
5. Frandson, R. W., W. L. Wilke, A. Dee Fails. 2009. *Anatomy and physiology of farm animals*. Wiley Blackwell.
6. Aughey, E., F. L. Frye. 2001. *Comparative Veterinary Histology*. Manson Publishing Ltd. London. UK.
7. Ramakrishna, V., K. M. Gadre. 2004. *A Systemic Histology of Domestic Animals*, 2th edn. Jaypee Brothers Medical, New Delhi.
8. Hebb, C. A., L. J. Linzell. 1970. Innervation of the mammary gland. A Histochemical study in the rabbit. *Histochem J*. 2(6): 491-505.
9. Hurley, W. L. 1989. Mammary gland Function during involution. *J Dairy Sci*. 72(6): 1637-1646.
10. Turner, C. E. 1996. The Anatomy of the Udder of Cattle and Domestic Animals. *Biol Reprod*. 55: 671- 675.
11. Linzell, L. J., M. Peaker. 1971. *Physiol Rev*. 51(3): 564-597.
12. William, G. L., W. R. McVey, J. F. Hunter. 1993. Mammary somatosensory pathways are not required for suckling-mediated inhibition of luteinizing hormone secretion and delay of ovulation in cows. *Biol Reprod*. 49: 1328-1337.